

JOHN WINTER, ALFREDO FIGUEREDO, STEVEN FISHER, and ELLEN QUATELA

LATE SALADOID BURIALS FROM ST. CROIX

INTRODUCTION

This report is the result of an archaeological assessment and salvage excavation carried out in April, May and June 1986 on Hemer's Peninsula of estate Judith's Fancy, St. Croix, U.S. Virgin Island.

The survey of this 74.5 acre property was made easier by the changes effected by landscape modification between 1958 and 1964. During these years, the Oxford Corporation and other parties bulldozed large areas down to bedrock, excavated canals and ponds, and filled in much bayfront with made land. The result is that large portions of the property can be dismissed by means of a cursory visual inspection as lacking in cultural resources.

The site that we are concerned with here is in a very unusual setting. It is on a rocky coralline shore, behind a lagoon sheltered by a reef. Though adjacent to Salt River Bay, it faces actually the open sea beyond the lagoon. The unnamed hill to the east-southeast of it affords little shelter from frequent northeasterly winds, which whip around it and through the site. It may not be inaccurate to state that at present, the site location seems as though it would be unattractive to settlement by people with a neolithic technology. It is likely, therefore, that the site is not *sensu stricto* a settlement, but rather the location of undisclosed special activities. In support of the foregoing may be cited the following: there is a large village site (SC 6 - Salt River Point) across the bay from our site; this village site was occupied during Period II b, when cultural deposits take place in our site.

As to previously reported sources for the study area, it turns out that the site reported by Gudmund Hatt (1924) and by him numbered '5', is in a different locality, and is therefore a different site from that which was also numbered '5' by Gary Vescelius (1952). We are here before a new site, which is neither Hatt's nor Vescelius'.

The pottery, in general, is homogenous as to style, forming a single component. This component is Aklian Saladoid, akin at once to the assemblages of the single component sites of Gun Creek, Virgin Gorda and Davis Beach, St. Croix, datable in this instance by relative means to about A.D. 400 - 450.

Saladoid ceramic styles of the Aklian pattern refer to the culture of the descendants of earlier Saladoid peoples after their society had progressed and adapted more fully to island life, occupying many environmental niches not perceived by their ancestors and making fuller use of their environment. This resulted in more widespread settlement and in proliferation of smaller and more isolated settlements. Smaller settlements and less specialized economic activity led to a decline in artistic achievement and also very likely to a degree of political and economic fragmentation. As such, Aklian styles are a structural simplification of earlier Saladoid pottery, tending to retain many procedural modes (beaker shape), but failing to retain many of the more complex conceptual modes (polychrome painting).

As previously mentioned, this site may have been the location of undisclosed special activities. The location of four human burials might lead us to consider a cemetery. All of the burials appear to have come from the same cultural level, however it would appear from the physical evidence that these burials had been disturbed prior to excavation as no burial was complete. What follows is a report on each burial.

BURIAL A

This individual was found lying on its back, face up in an apparent flexed position. A partial cranium was reconstructed from the fragments of a frontal bone, right and left parietal bones, and occipital bone. This reconstruction produced a forehead with a flattened condition. In addition, the superior nuchal line of the occipital bone and the supra orbital ridges of the frontal bone are not very pronounced. The remaining bones consist of the shafts of the left humerus, right femur, and left fibula. The proximal end and shaft of the right radius and four maxillary teeth are also present. As the bones lacked pronounced muscle attachment areas and discriminant function analysis on the incisors and canines produced score of 0.547, this individual is classified as a female. The sagittal suture is completely fused, which could indicate that she was over 30 years of age at death.

Unfortunately, none of the long bones retained their proximal and distal ends, so that stature reconstruction was impossible.

No pathological conditions are observed on this individual, however a discontinuous morphological trait is present on the frontal bone: a supra orbital notch above the right eye orbit. Four maxillary teeth were studied: the first left and right incisors, the second left incisor, and left canine. The incisors exhibit the genetic condition known as shovel-shaping. No dental pathologies are observed, however dental wear is slight to moderate. The wear of the first incisors is rated a 4 (Smith), with the left incisor exhibiting wear on the lingual surface. The second left incisor and left canine are rated a 2 (Smith). The type of wear on the first incisors may be the result of this individual using her teeth for some kind of processing activity.

BURIAL B

This individual was greatly disturbed and no reference can be made as to burial position. A partial cranium was reconstructed from fragments of the frontal bone, right parietal bone and occipital bone. The forehead region appears to exhibit a flattened condition. The supra orbital ridges of the frontal bone are moderately robust and the superior orbital margins are rounded. The right temporal line is well pronounced. The remaining bones of this individual consist of the shafts of the right and left humerus, with the right being more developed, the right fibula and right radius. The mandible is developed in the gnathion region but it lacks the ramii (Figure 1). All the permanent teeth are erupted in the mandible. Discriminant function analysis was carried out on the teeth to yield a score of 0.987. This individual is therefore being classified as a male over 25 years.

Unfortunately, none of the long bones retained their proximal and distal ends, so that stature reconstruction was not possible.

Three discontinuous morphological traits are present: two supra orbital foramen are above each eye orbit, no third molar is present in the mandible, and wormian bones are found in the lambdoidal suture region between the right parietal and occipital bones.

There is a slight calculus (tartar) formation on the lingual and distal cervical margins of the first and second left mandibular molars. Symmetrical fissures can be observed in both second and third mandibular molars in the mid-line of the tooth on the buccal surface (Figure 2). The second mandibular molars both exhibit a Y-4 cusp pattern, whereas the first left molar has a Y-5 pattern. The dental wear is slight to moderate. The maxillary incisors average 4 (Smith), with the central incisors having the most wear. The left mandibular molars average 3 (Smith) and 18.5 (Scott). The left maxillary molars average 3.5 (Smith) and 16 (Scott), while the first right molar is 4 (Smith) and 20 (Scott).

BURIAL C

This individual was found on its back, face up in a flexed position. A nearly complete skull was reconstructed, however facial bones are lacking. The cranium exhibits fronto-occipital cranial deformation with a cephalic index of 88.6. The overall appearance of the cranium and mandible is very gracile and the angle of the mandibular ramus is obtuse. The remaining bones of this individual consist of the shafts of the left and right femurs, tibiae, and fibulae. The left humerus is missing the proximal end, although there is a mildly developed deltoid tuberosity. The right and left ulnae both lack distal ends, while the left radius consists of a shaft with the radial tuberosity. The acromial end of the right clavicle and the right and left glenoid cavities of the scapulae were present as well. Based upon the gracile features of the bones, the following discriminant function analyses: mandible (222, 307.6, 344.9), base of the cranium (0.72), and a measurement of the glenoid cavity, 32.5 mm, this individual is being classified as an adult female. As the sagittal suture is completely closed and pronounced mandibular alveolar resorption has taken place, this individual was over age 35.

Unfortunately, none of the long bones retained their proximal and distal ends, so that stature reconstruction was not possible.

Several anomalies were observed on this individual. There are supra orbital notches above each orbit, a discontinuous trait. The area below the coronoid process on the anterior surface of both ulnae have pronounced attachment areas for the oblique ligament, perhaps indicating strong use of the forearms (Figure 3). The superior surface of the odontoid process had developed an ossification of the apical ligament (Figure 4). A pathological condition exists between the left articular surface of the third and fourth cervical vertebrae. The inferior surface of the third and the superior surface of the fourth (figure 5) are misshapened and reduced in size. The last two conditions would indicate a skeletal muscle adaptation to a bone disorder.

The mandible exhibits various stages of alveolar resorption. This occurs behind the mandibular canine, the area of the central incisors, and between the first right pre-molar and last molar. The last mandibular molar is rotted down to the root, while the first right pre-molar has a wear pattern of 7 (Smith) with a lingual to buccal

slope (Figure 6). This could be the result of processing materials.

BURIAL D

This individual was lying on its side in a flexed position with a diorite peltoid stone near the abdomen region. There are no cranial bones, only post-cranial material. These bones consist of the shafts of the right and left tibias, femurs, ulnas, radii and left fibula. The right humerus is missing the proximal end. Unfortunately, none of these bones retained the proximal and distal ends, so that stature reconstruction is not possible. There are no pathologies on the bones, however the femurs have pronounced linea aspera. In addition, the left talus was subjected to discriminant function analysis to yield a score of 37.2. No epiphyseal growth lines were observed on the long bones, so this individual is classified as an adult male over 25.

CONCLUSIONS

Although four individuals do not make a population, they could be used to yield some information about the Aklian populations. We believe that the flexed positions of the burials result from the individual being wrapped and carried in a cotton hammock. After being placed in the ground, the final resting position occurs. Bacterial disease apparently caused the death of these individuals as no traumatic conditions were observed. As to a cause of bacterial infection, this could result from the excess calculus build-up at the gum line. This would cause irritation and inflammation, eventually leading to tooth loss and alveolar resorption permitting the bacteria to enter the blood stream

The even dental wear of the molar teeth tends to indicate that the diet was fibrous and abrasive. The lack of abnormal grinding marks could indicate that the lifestyle of these people was not very stressful. The lack of caries could indicate a lack of large quantities of processed carbohydrates. This dietary indication would be characteristic of a time period where these Aklian Saladoid people were exploiting various environmental niches. Additional skeletal material will be necessary to confirm or deny these statements.

BIBLIOGRAPHY

Bass, William M.
1987 *Human Osteology: A Field Laboratory Manual*. Columbia, MO: Missouri Archaeological Society.

Figueredo, Alfredo E.
1974 West Indian Prehistory - Saladoid Culture. *The Weekly Journal*, Vol. II, no. 41, p. 58.

1980 Pottery from Gun Creek, Virgin Gorda. *Journal of the Virgin Islands Archaeological Society*, no. 9, pp. 27-30.

1986 Phase I Cultural Resources Survey of Sugar Bay Land Development, Ltd., Estate Judith's Fancy, St. Croix. MS

Giles, Eugene

1964 Sex Determination by Discriminant Function Analysis of the Mandible. *American Journal of Physical Anthropology* 22: 129-136.

Hatt, Gudmund

1924 Archaeology of the Virgin Islands. *Proceedings of the XXI International Congress of Americanists*, Vol. I, pp. 29-42.

Holland, Thomas

1986 Sex Determination of Fragmentary Crania by Analysis of the Cranial Base. *American Journal of Physical Anthropology* 70: 203-208.

Krogman, Wilton

1962 The Human Skeleton, in: *Forensic Medicine*. Springfield: C.C. Thomas.

Ortner, D.J. and W.G.J. Putschar

1981 *Identification of Pathological Conditions in Human Skeletal Remains*. Washington, D.C.: Smithsonian Institution Press.

Scott, E.C.

1979 Dental Wear Scoring Techniques. *American Journal of Physical Anthropology* 51: 211-218.

Smith, B. Holly

1984 Patterns of Molar Wear in Hunter-Gatherers and Agriculturalists. *American Journal of Physical Anthropology* 63: 39-56.

Steele, D. Gentry and Claud A. Bramblett

1988 *The Anatomy and Biology of the Human Skeleton*. College Station, TX: Texas A & M Press.

Vescelius, Gary S.

1952 The Cultural Chronology of St. Croix. MS.

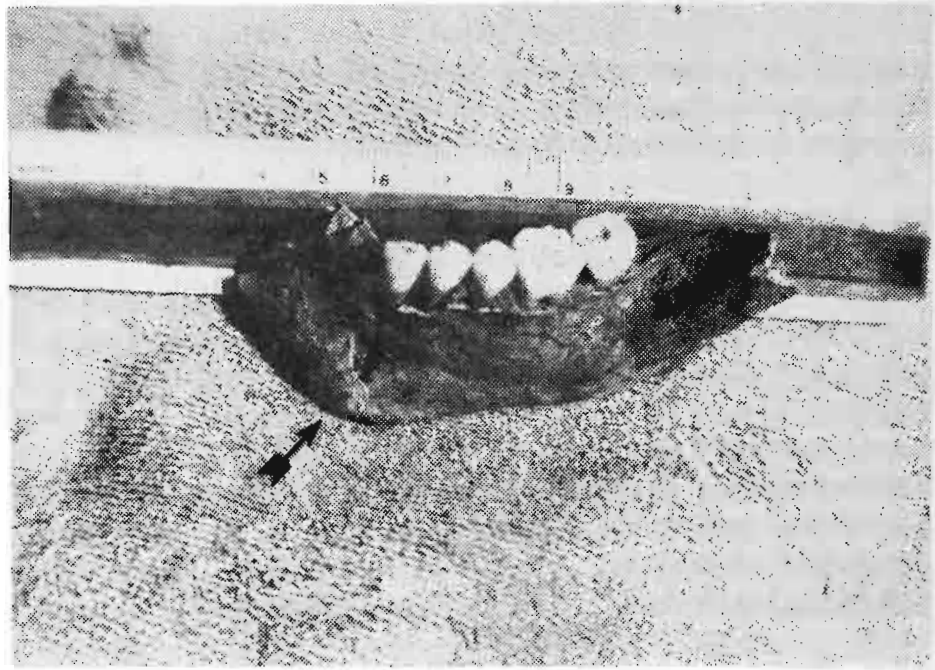


Fig. 1. Burial B: Developed Gnathion Region.

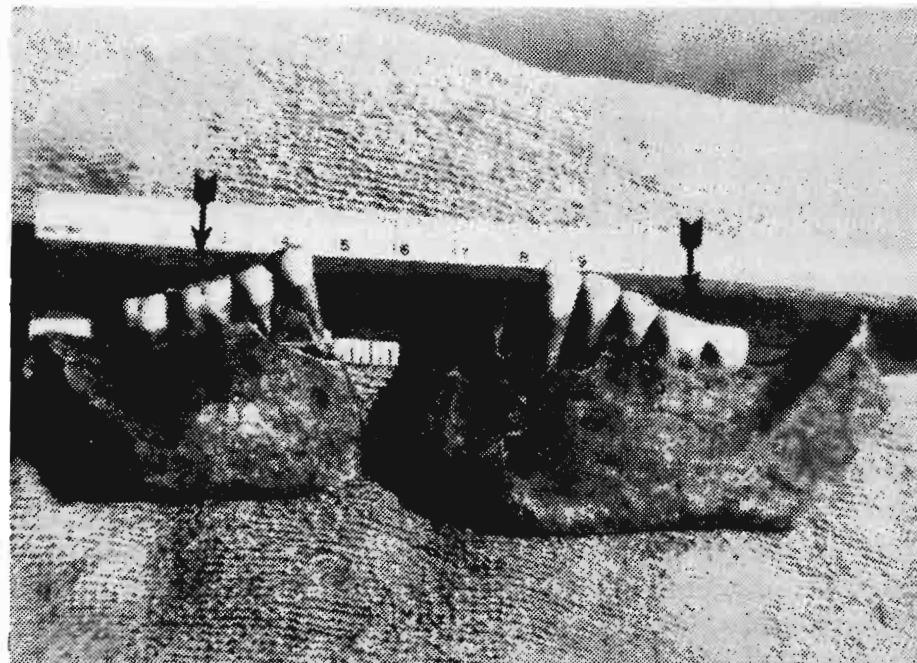


Fig. 2. Burial B: Symmetrical Molar Fissures.

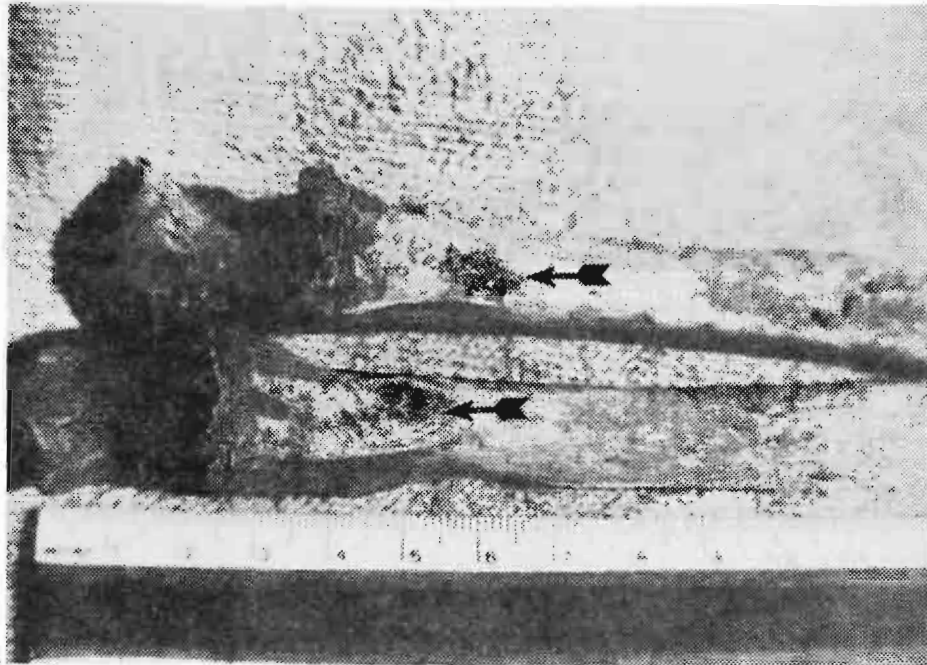


Fig. 3. Burial C: Ulna oblique Ligament Depressions.



Fig. 4. Burial C: Ossification of Apical Ligament.



Fig. 5. Burial C: Deformity of Fourth Cervical.

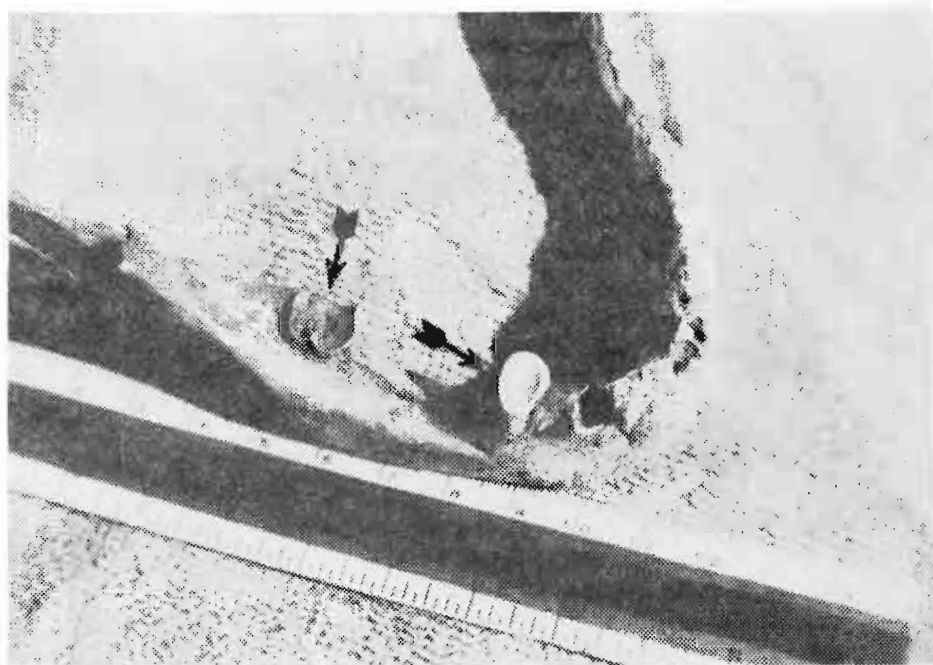

Fig. 6. Burial C: Mandibular Wear of Adult Female.